

Reverse Shoulder Arthroplasty for the Treatment of Rotator Cuff Deficiency

A Concise Follow-up, at a Minimum of 10 Years, of Previous Reports*

Derek J. Cuff, MD, Derek R. Pupello, MBA, Brandon G. Santoni, PhD, Rachel E. Clark, BS, CCRP, and Mark A. Frankle, MD

Investigation performed at the Florida Orthopaedic Institute and the Foundation for Orthopaedic Research and Education, Tampa, Florida

Abstract: We previously evaluated 94 patients (96 shoulders) who underwent reverse shoulder arthroplasty using a central compressive screw with 5.0-mm peripheral locking screws for baseplate fixation and a center of rotation lateral to the glenoid as treatment for end-stage rotator cuff deficiency. The purpose of this study was to report updated results at a minimum follow-up of 10 years. Forty patients (42 shoulders) were available for clinical follow-up. In the patients available for study, implant survivorship, with the end point being revision for any reason, was 90.7%. Since our 5-year report, 2 patients underwent revision surgery; 1 patient sustained a periprosthetic fracture 7 years postoperatively and 1 patient had a dislocation because of chronic shoulder instability at 8 years postoperatively. At a minimum follow-up of 10 years, the patients continued to maintain their improved outcome scores and range of motion, which were comparable with earlier follow-up evaluations.

Level of Evidence: Therapeutic Level IV. See Instructions for Authors for a complete description of levels of evidence.

Background

We previously reported on a cohort of patients who were treated between February 2004 and March 2005 with a reverse shoulder arthroplasty (RSA) as a part of a U.S. Food and Drug Administration (FDA) Investigational Device Exemption (IDE) study^{1,2}. The implant that was used had a central 6.5-mm-diameter compressive screw with 5.0-mm peripheral locking screws for baseplate fixation and a glenosphere with a center of rotation lateral to the glenoid (Reverse Shoulder Prosthesis; DJO Surgical). The surgical technique positioned the glenosphere with inferior tilt in relation to the face of the glenoid by preferentially reaming the inferior aspect of the glenoid. The humeral component that was used in this study had a 135° neck-shaft angle and was placed in 30° of retroversion. The patients included in the study had end-stage rotator cuff deficiency that was due to a wide variety of pathological conditions, including primary rotator cuff deficiency, failed previous rotator cuff

operations, failed previous arthroplasty, and proximal humeral nonunion.

At the 5-year follow-up point, these patients had preoperative to postoperative improvements in their clinical outcome scores and range of motion and a 94% implant survival rate¹. Radiographic analysis of this cohort at that time revealed a 9% rate of scapular notching and no glenoid baseplate loosening or baseplate failures. The purpose of this study was to examine the midterm results at a minimum of 10 years of follow-up focusing on survivorship of the implant, clinical outcomes, and radiographic findings.

Methods

Subsequent to our 5-year report, 24 patients had died and 10 patients were lost to follow-up, leaving 40 patients (42 shoulders) for evaluation (Fig. 1). With respect to indications for surgery, 19 shoulders (45.2%) had primary rotator cuff

*Original Publications

Cuff D, Pupello D, Virani N, Levy J, Frankle M. Reverse shoulder arthroplasty for the treatment of rotator cuff deficiency. *J Bone Joint Surg Am.* 2008 Jun;90(6):1244-51.

Cuff D, Clark R, Pupello D, Frankle M. Reverse shoulder arthroplasty for the treatment of rotator cuff deficiency: a concise follow-up, at a minimum of 5 years, of a previous report. *J Bone Joint Surg Am.* 2012 Nov;94(21):1996-2000.

Disclosure: This study was supported in part by a research grant for the initial U.S. Food and Drug Administration study from DJO Global, which is the manufacturer of the device used in this study. On the **Disclosure of Potential Conflicts of Interest** forms, which are provided with the online version of the article, one or more of the authors checked "yes" to indicate that the author had a relevant financial relationship in the biomedical arena outside the submitted work and "yes" to indicate that the author had a patent and/or copyright, planned, pending, or issued, for the device that is the subject of this article (<http://links.lww.com/JBJS/E372>).

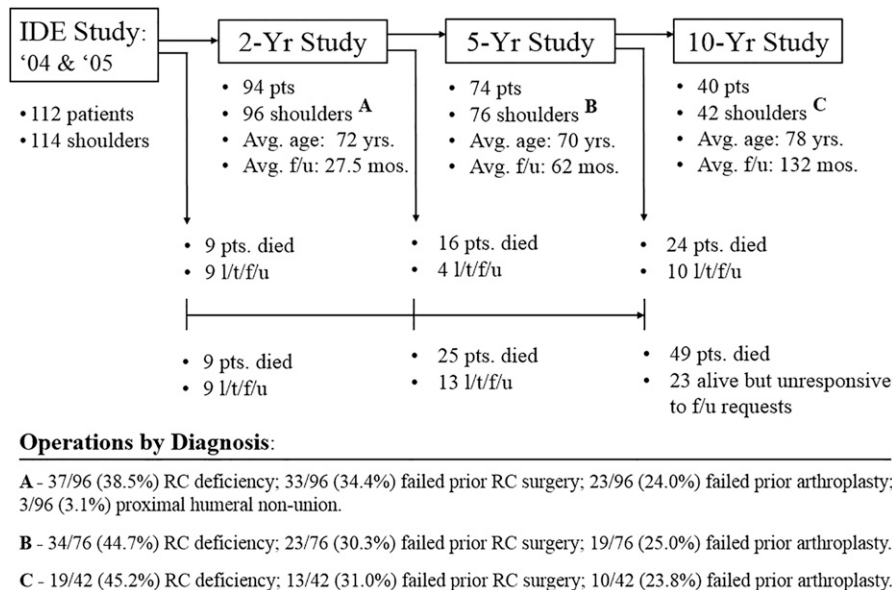


Fig. 1
Flowchart illustrating patients studied clinically and those lost to follow-up (l/t/f/u) over the course of the 10-year study. The distributions of operations performed according to the preoperative diagnosis for the 2, 5, and 10-year studies are also provided. Pts = patients, and RC = rotator cuff.

deficiency with accompanying arthritis, 13 shoulders (31.0%) had previous failed rotator cuff operations, and 10 shoulders (23.8%) had a failed arthroplasty and cuff deficiency.

The average age of the available patients was 78 years (range, 62 to 99 years); 22 were female and 18 were male. The average time to follow-up was 132 months (range, 120 to 147 months). The surgical technique and postoperative protocol for this procedure have previously been described in detail³⁻⁵.

The patients were followed yearly and the same clinical outcome scores (American Shoulder and Elbow Surgeons [ASES] score and Simple Shoulder Test [SST]) that were utilized in our previous study were updated at the last follow-up evaluation. Patient questionnaires included a self-assessment of range of motion as indicated by a mark placed at the highest attainable motion on a picture. This varied somewhat from our initial 2-year report as some patients did not have a video made at the 10-year follow-up point, but all were able to fill out the assessment form. The same patient-reported methodology for range-of-motion assessment was used in our 5-year report¹.

Implant survivorship analysis, with revision surgery for any reason as the end point, was performed. Survival was defined as the percentage of shoulders in the available patients who did not require a revision surgery over the 10-year study period. One of the patients who had been lost to follow-up prior to the 10-year mark had had a revision 8 years after the index procedure because of recurrent instability and was, therefore, included in the survivorship analysis.

Radiographic analysis was performed by an independent observer in the same standardized fashion as we reported previously on our 2-year and 5-year follow-up studies. Baseplate fixation was graded as stable (no evidence of radiolucency at the baseplate-bone interface or around any screw), at risk (>1 mm of circumferential radiolucency at the baseplate-bone

interface or around any 1 screw), or loose (>1 mm of radiolucency around the baseplate-bone interface and around all screws, or the existence of a shift in the position of the baseplate). Humeral loosening was measured using the grading system described by Sperling et al.⁶. Radiographs were also evaluated for evidence of dislocation, scapular notching on the basis of the criteria described by Sirveaux et al., and screw breakage⁷.

Statistical Analysis

Preoperative and postoperative clinical outcome data were compared using a paired t test and commercially available statistical software (SPSS; IBM).

Results

At a minimum follow-up of 10 years, the patients continued to maintain their improved outcome scores and range of motion (Table I). Forty patients had complete self-reported functional data (ASES score, visual analog scale [VAS] pain score, SST, and range of motion) for analysis, the majority of which was collected either by telephone or through mail correspondence. Eight patients (20%) in the current study visited our facility at a minimum of 10 years postoperatively and had radiographic evaluation. Their radiographs were evaluated for evidence of hardware failure and/or scapular notching.

Implant survivorship at 120 months was 90.7% (39 of 43 shoulders) (Table II). A total of 4 patients in the 10-year cohort had undergone revision surgery: 1 was included in the original 2-year study, an additional revision was captured in the 2 to 5-year follow-up interval, and 2 additional patients underwent revision between 5 and 10 years after the index procedure. The 2 more recent revisions were for recurrent instability (1 shoulder)

TABLE I Preoperative and Postoperative Outcomes According to Preoperative Diagnosis for All 42 Shoulders and 3 Subgroups*

	Preop.	5-Year Evaluation†	Latest Follow-up Evaluation†	P Value‡
Total ASES score				
All patients	35 (0-65)	77 (7-100)	74 (45-90)	0.444
Primary cuff deficiency	36 (0-63)	79 (17-100)	76 (58-90)	0.679
Previous rotator cuff surgery	41 (18-65)	75 (7-100)	77 (65-85)	0.899
Failed arthroplasty	27 (0-63)	72 (37-97)	68 (45-83)	0.223
ASES pain score				
All patients	19 (0-43)	42 (0-50)	44 (35-50)	0.352
Primary cuff deficiency	17 (0-30)	44 (5-50)	44 (35-50)	0.807
Previous rotator cuff surgery	23 (10-43)	38 (0-50; p = 0.029)	44 (35-50)	0.265
Failed arthroplasty	16 (3-43)	45 (30-50)	45 (35-50)	1.00
SST score				
All patients	2 (0-7)	8 (0-12)	7 (0-12)	0.057
Primary cuff deficiency	2 (0-7)	8 (2-12)	7 (1-12)	0.103
Previous rotator cuff surgery	2 (0-6)	7 (1-12)	7 (3-12)	0.766
Failed arthroplasty	2 (0-7)	7 (0-12)	5 (0-12; p = 0.013)	0.056
Forward flexion (deg)				
All patients	70 (10-152)	144 (11-180)	126 (0-180)	0.049
Primary cuff deficiency	85 (34-152)	157 (100-180)	132 (10-180; p = 0.002)	0.119
Previous rotator cuff surgery	49 (10-100)	148 (50-180)	140 (50-180)	0.572
Failed arthroplasty	68 (10-126)	117 (11-180; p = 0.057)	98 (0-180; p = 0.294)	0.292
Abduction (deg)				
All patients	65 (10-159)	129 (50-180)	117 (0-180)	0.167
Primary cuff deficiency	77 (35-159)	153 (90-180)	137 (45-180)	0.357
Previous rotator cuff surgery	52 (22-82)	123 (50-180)	109 (0-180)	0.422
Failed arthroplasty	60 (10-158)	94 (50-150; p = 0.121)	89 (0-150; p = 0.214)	0.495
External rotation (deg)				
All patients	18 (-40-78)	53 (-60-100)	40 (-30-90)	0.105
Primary cuff deficiency	21 (-40-78)	56 (-60-90; p = 0.009)	53 (0-90; p = 0.002)	0.705
Previous rotator cuff surgery	22 (-17-50)	44 (-60-100; p = 0.168)	43 (-30-90; p = 0.112)	0.891
Failed arthroplasty	8 (-21-44)	56 (10-90)	14 (-30-90; p = 0.603)	0.010

*Data are expressed as the mean with the range in parentheses. †All comparisons of preoperative and postoperative values have a p value of <0.001 unless otherwise indicated. ‡Comparison of 5-year follow-up with latest follow-up.

and periprosthetic midshaft humeral fracture (1 shoulder). **There were no mechanical baseplate failures.**

Table I summarizes the comparison of preoperative and postoperative outcome scores at the time of final follow-up. The patients had maintained their gains in total average ASES scores, with an improvement from a preoperative score of 35 to a postoperative score of 74 at the last follow-up ($p < 0.001$). Similar gains had been maintained with respect to average SST scores, with an improvement from a preoperative score of 2 to a postoperative score of 7 at the last follow-up ($p < 0.001$). The outcome scores were also stratified by the preoperative diagnosis and these data are presented in Table I. With respect to range of motion, the average forward flexion increased from 70° preoperatively to 126° at the last follow-up ($p < 0.001$); average abduction, from 65° to 117° ($p < 0.001$); and average external rotation, from 18° to 40° ($p < 0.001$).

Radiographic analysis revealed no evidence of radiolucency around the baseplate or baseplate screws in the 8 patients with 10 years of radiographic follow-up. At 10 years, 1 patient demonstrated asymptomatic humeral radiolucencies, which were initially identified radiographically at 6 and 7 years postoperatively. One patient with complete radiographic follow-up had grade-1 notching at the 10-year mark. This patient had not had notching at 2 or 5 years as determined from radiographic evaluation.

All 40 patients had a minimum radiographic follow-up of 2 years (average, 68 months) and, of the entire cohort available for study, 5 patients (5 shoulders) displayed grade-1 notching during the study period. A single patient (1 shoulder) displayed grade-2 notching, which was noted radiographically at 32 months; however, this visit to our clinic at approximately 3 years was the patient's last and all subsequent information from this

TABLE II Complications Requiring Revision Surgery According to Preoperative Diagnosis

	2-Year Follow-up (94 Patients, 96 Shoulders)	2 to 5-Year Follow-up (74 Patients, 76 Shoulders)*	Since 5-Year Follow-up (41 Patients, 43 Shoulders)†‡
Base plate failure	0	0	0
Recurrent instability	2	1	1
Primary cuff deficiency	0	0	1
Previous rotator cuff surgery	1	0	0
Failed arthroplasty	1	1	0
Humeral loosening	1	0	0
Primary cuff deficiency	0	0	0
Previous rotator cuff surgery	0	0	0
Failed arthroplasty	1	0	0
Resorption of proximal humeral allograft	0	1	0
Primary cuff deficiency	0	0	0
Previous rotator cuff surgery	0	0	0
Failed arthroplasty	0	1	0
Periprosthetic fracture	0	0	1
Primary cuff deficiency	0	0	0
Previous rotator cuff surgery	0	0	0
Failed arthroplasty	0	0	1
Survivorship	97%	94%	91%

*Three patients requiring revision at 2 years were included in the 5-year study. Two additional revisions occurred between 2 and 5 years. †One patient was included in the survivorship analysis because of a revision at 8 years, resulting in 43 shoulders available for survivorship analysis. ‡Two patients requiring revision at 5 years were included in the 10-year study. Two additional revisions in 1 patient occurred between 5 and 10 years. This patient was lost to follow-up at 10 years, and the patient's outcomes and range of motion data were not available for analysis.

patient was collected via telephone and/or mail correspondence. Thus, the progression of the notching, if any, is unknown. The average onset to radiographic evidence of scapular notching was 49.1 months (range, 25.7 to 115.3 months) in the 6 of the 40 patients in whom radiographic evidence was identified at any time during the postoperative course.

There were 2 additional patients in the cohort who required revision surgery (Table II) since our previous 5-year report. One patient sustained a periprosthetic midshaft humeral fracture 7 years after the index procedure, which was performed after a failed hemiarthroplasty. The second revision, which was for recurrent instability, was revised with another reverse prosthesis at 8 years. This patient had a self-reported history of chronic falling, beginning in 2011, and sustained (1) a scapular spine fracture in 2012 that was treated nonoperatively and (2) a prosthetic dislocation 4 months later that could not be managed via closed reduction. The patient had a revision with a reverse prosthesis in July 2012 and had a dislocation again in October 2012 when rising from a chair. This patient was unreachable for follow-up at the 10-year time point.

Conclusions

The majority of patients who underwent RSA in our study maintained their improved function with durable clinical

results at a minimum follow-up of 10 years. In our previous reports, we noted that the addition of 5.0-mm peripheral locking screws for baseplate fixation had eliminated early baseplate failures that had been seen in an earlier series of patients in whom a glenosphere with a center of rotation lateral to the glenoid had been utilized^{1,2,4}. We noted that the locking screws provided improved early fixation and allowed for osseous ingrowth into the baseplate in order to achieve good long-term fixation^{2,8}. The results at a minimum follow-up of 10 years in the current study support this finding as we observed good durability of this implant, with a survivorship of 91% using revision as an end point.

Lastly, we noted an increase in shoulder motion between the 2 and 5-year follow-up studies, which we attributed to the different method of assessment. Sirveaux et al.⁷ and Guery et al.⁹, in longer-term studies in which the Grammont-style RSA was used, demonstrated a functional deterioration and increase in pain levels in some patients after the 6-year follow-up point. At the 10-year mark, we did not observe any consistent trend of an increase in shoulder pain, and almost 70% of the patient cohort reported either a decrease in pain or no change in shoulder pain between their 5 and 10-year follow-up visits. However, between the 5 and 10-year studies, we did notice a decrease in shoulder motion in all planes,

albeit small, for all preoperative diagnoses. In the context of decreased motion without a concomitant increase in pain at 10 years, we attributed this finding to the advanced age of our patient cohort. ■

Derek J. Cuff, MD¹
Derek R. Pupello, MBA²
Brandon G. Santoni, PhD²

Rachel E. Clark, BS, CCRP²
Mark A. Frankle, MD³

¹Suncoast Orthopaedic Surgery & Sports Medicine, Venice, Florida

²Foundation for Orthopaedic Research and Education, Tampa, Florida

³Florida Orthopaedic Institute, Tampa, Florida

E-mail address for M.A. Frankle: mfrankle@floridaortho.com

ORCID iD for M.A. Frankle: [0000-0001-6427-0665](https://orcid.org/0000-0001-6427-0665)

References

1. Cuff D, Clark R, Pupello D, Frankle M. Reverse shoulder arthroplasty for the treatment of rotator cuff deficiency: a concise follow-up, at a minimum of five years, of a previous report. *J Bone Joint Surg Am.* 2012 Nov 7;94(21):1996-2000.
2. Cuff D, Pupello D, Virani N, Levy J, Frankle M. Reverse shoulder arthroplasty for the treatment of rotator cuff deficiency. *J Bone Joint Surg Am.* 2008 Jun;90(6):1244-51.
3. Frankle M, Levy JC, Pupello D, Siegal S, Saleem A, Mighell M, Vasey M. The Reverse Shoulder Prosthesis for glenohumeral arthritis associated with severe rotator cuff deficiency. A minimum two-year follow-up study of sixty patients. *Surgical technique. J Bone Joint Surg Am.* 2006 Sep;88(Suppl 1 Pt 2):178-90.
4. Frankle M, Siegal S, Pupello D, Saleem A, Mighell M, Vasey M. The Reverse Shoulder Prosthesis for glenohumeral arthritis associated with severe rotator cuff deficiency. A minimum two-year follow-up study of sixty patients. *J Bone Joint Surg Am.* 2005 Aug;87(8):1697-705.
5. Levy J, Frankle M, Mighell M, Pupello D. The use of the Reverse Shoulder Prosthesis for the treatment of failed hemiarthroplasty for proximal humeral fracture. *J Bone Joint Surg Am.* 2007 Feb;89(2):292-300.
6. Sperling JW, Cofield RH, O'Driscoll SW, Torchia ME, Rowland CM. Radiographic assessment of ingrowth total shoulder arthroplasty. *J Shoulder Elbow Surg.* 2000 Nov-Dec;9(6):507-13.
7. Sirveaux F, Favard L, Oudet D, Huquet D, Walch G, Molé D. Grammont inverted total shoulder arthroplasty in the treatment of glenohumeral osteoarthritis with massive rupture of the cuff. Results of a multicentre study of 80 shoulders. *J Bone Joint Surg Br.* 2004 Apr;86(3):388-95.
8. Harman M, Frankle M, Vasey M, Banks S. Initial glenoid component fixation in "reverse" total shoulder arthroplasty: a biomechanical evaluation. *J Shoulder Elbow Surg.* 2005 Jan-Feb;14(1)(Suppl S):162S-7S.
9. Guery J, Favard L, Sirveaux F, Oudet D, Mole D, Walch G. Reverse total shoulder arthroplasty. Survivorship analysis of eighty replacements followed for five to ten years. *J Bone Joint Surg Am.* 2006 Aug;88(8):1742-7.